Computer-Aided Detection Systems for Digital Mammography

Marlen Perez-Diaz[1](✉), Ruben Orozco-Morales[1], Eduardo Suarez-Aday[1], and Rosana Pirchio[2]

[1] Automatic and Computer Systems Department, Universidad Central "Marta Abreu de las Villas", Camajuani Road km 5 ½, 52830 Santa Clara, Cuba
mperez@uclv.edu.cu

[2] Medical Physics Department, Atomic Energy National Commission, Buenos Aires, Argentina

Abstract. Mammography is the typical diagnostic test for early detection of breast cancer. The presence of microcalcifications and masses in the images may be an indicator of the disease. The microcalcifications size is very small, so, in many cases, they are not visible from medical images by radiologists. On the other hand, masses can be also undetectable if image contrast is not good enough. The computer-aided detection (CAD) systems are useful tools in facilitating the physician´s diagnosis. The CAD system proposed in this work is aimed at improving image quality based on image processing. On these improved images, it segments the mammary gland and highlights the presence of microcalcifications and masses. The system improves image contrast by means of convolution filters, it also eliminates artifacts by means of morphological opening and closing and Laplacian filtering, and uses entropy-based methods for segmentation of the gland and morphological filtering and histogram readjustment to enhance microcalcifications in the image. Masses are detected using an iterative contrast increase method. The system was tested with an annotated database (DB) *MIAS*, in oblique lateral views of glandular, glandular-dense and predominantly adipose breasts, which included images of malignant and benign lesions and other breast images without them. The system was evaluated with respect to the DB annotation, for a sample of 115 images. The performance of the system revealed a sensitivity of 93.2%, a specificity of 85.3%, a precision of 90.4% and an accuracy of 92%.

Keywords: Computed Aided Diagnostic Systems (CAD) · Mammography · Microcalcifications and masses

1 Introduction

Mammography has proven to be the most effective method for early breast cancer detection. The presence of microcalcifications and masses are indicators of the disease.

Microcalcifications are difficult to detect due to their small size. Among the proposed solutions, in [1] the performance of five algorithms of enhancement of images has been analyzed. In particular, Local Range Modification and Redundant Discrete Wavelet have an effectiveness of 93.2% and 92.6%, respectively. Another relevant

C. A. González Díaz et al. (Eds.): CLAIB 2019, IFMBE Proceedings 75, pp. 265–271, 2020.
https://doi.org/10.1007/978-3-030-30648-9_34

solution was proposed in [2], using a knowledge-based system, which uses local features extracted with a filter bank. In [3] the use of the contour transform and simplified pulse coupling neural networks are introduced to achieve a sensitivity of 96.3% and a specificity of 94.7%. In the last decades, methods that include artificial intelligence have also been used [4].

The masses detection is another important aspect. However, its visualization can be very complex when the mass is very small or the breast tissue is very dense, since it does not produce a noticeable peak in the image histogram. Various methods have been proposed for segmentation of masses. Among them, a scheme in two parts that forms homogeneous blocks first and later uses a quantification of the intensities is introduced [5]; as well as a combination of the entropy of Havrda-Charvat with the method of Otsu's thresholding to obtain a sensitivity of 93% [6]. Recently, the principal component analysis has been used [7]. Also, a two-stage adaptive thresholding method has been proposed [3] with an average sensitivity of 93.5%.

Computer-Aided Diagnostic (CAD) systems have been developed to support and facilitate the radiologists' work. Most of these systems consist of four stages: pre-processing of images, segmentation of the previously described lesions and their extraction of characteristics and classification.

During the pre-processing stage, contrast enhancement techniques are useful since they guarantee a successful subsequent segmentation. In addition to classical methods, such as histogram equalization, transform-based methods, or those based on image decomposition, other strategies have been applied based on histogram optimization [8]. However, these methods are generally computationally expensive. Some examples are: [1, 9–11].

In this work, the efficacy for contrast enhancement in digital images of mammography for microcalcifications is evaluated based on morphological operations in gray scale, known as black top hat and white top hat [1]. These state-of-the-art methods have proven their effectiveness in other contexts. Furthermore, the performance of several methods of masses segmentation based on thresholding was examined by applying different entropy criteria, such as the two-dimensional Tsallis, and several implementations of Shannon entropy [12–15], but in the case of mammography is used for the first time.

2 Materials and Methods

The proposed System includes the pre-processing of the image, the segmentation of the gland, the extraction of lesions characteristics (masses and microcalcifications) and the evaluation of the system. During the pre-processing stage the contrast is enhanced by highlighting the regions of greatest interest. The convolution filters H1, H2, H3 and H4 of Matlab were used for this purpose. This achieves lighting effects, sharpening and edge enhancement.

The artifacts that are not of interest for the study are eliminated. A morphological opening procedure is applied, using a structure element (strel). To remove the labels, the image is converted to binary, using the Laplacian-based ridge [16]. For this purpose, several simple leveling methods (bi-class) based on the entropy of the image are

used for the first time in this case. The used entropy-based thresholding methods have been: maximum entropy (ME), based on the classical definition of *Shannon* entropy [6], the improved version of the *Kapur* method [5] and the two-dimensional implementation introduced from the *Tsallis* entropy [17]. To determine the optimal threshold, the opinion of an experienced radiologist was asked, just to guarantee that the visual appearance of images were not distant from the typical ones. With it, a fine adjustment was made, which consisted of modifying the threshold obtained with each method, multiplying them by a factor k. In addition, a readjustment of the image was made, extending the pixels to the whole gray scale in the histogram.

Then morphological filtering is used for the enhancement of microcalcifications images. To do this, a grayscale erosion is applied with a circular geometry strel with 3 pixels of radius and flat top to increase the size of these objects and make them brighter. The dilation operator increases the size of the bright regions and decreases the size of the objects and the dark regions in the image.

In order to enhance the contrast between the identified objects in the image, morphological transformations in white top-hat and black top-hat gray scale are used. For the mass image enhancement, it was also essential to determine the shape and size of the strel. To do this, an iterative procedure is implemented based on a gradual increase of the strel diameter in each iteration, determining in each case the value of the contrast increase ratio (CIR), until an optimum result is obtained with a value of 20 pixels. The process ends when the CIR of an iteration is less than the previous one. This procedure is also new in the mammography case.

$$CIR = \frac{\sum_{(x,y)\epsilon R}\left(C(x,y) - \hat{\mathrm{C}}(\mathrm{x},\mathrm{y})\right)^2}{\sum_{(c,y)\epsilon R} C^2(x,y)} \tag{1}$$

Where R is the region of interest, while C and $\hat{\mathrm{C}}$ are the local contrasts in the original and enhanced images respectively.

To evaluate the system, 115 images of the database (BD) MiniMammographic were used. In each image, a normal or abnormal region was selected to perform a forced observation task, by comparison with the DB annotation. To evaluate the performance of the designed system, the results that the radiologist detected against the BD annotation were compared. From these elements, the accuracy, precision, sensitivity and specificity of the system were calculated.

$$\text{Accuracy}: \frac{Vp + Vn}{Vp + Vn + Fp + Fn} \tag{2}$$

$$\text{Precision}: \frac{Vp}{Vp + Fp} \tag{3}$$

$$\text{Sensitivity}: \frac{Vp}{Vp + Fn} \tag{4}$$

$$\text{Specificity}: \frac{Vn}{Vn + Fp} \tag{5}$$

Where *Vp* are the true positive, *Vn* are the true negative, *Fn* are the false positive and *Fn* are the False negatives.

3 Results

The H4 filter displayed the best results of image contrast enhancement and edge enhancement and was the one selected to use with the images for the different levels of glandularity. The thresholding methods employed, based on entropy, showed different results. Some images were over-segmented but in others, a lot of extra tissue was included. The results of these methods were averaged obtaining the best results. Figure 1 shows an example of the system's performance up to this point. The values of the fine segmentation correction coefficient (k) were between 0.6–1.0.

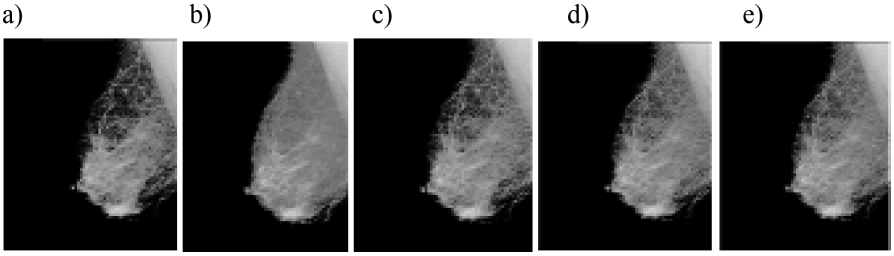

Fig. 1. Original image, enhanced and readjusted, with artifacts removed and subjected to different thresholding methods: (a) Method 1 Thr = 144 and k = 0.8, (b) Method 2 Thr = 127 and k = 1, (c) Method 3 Trh = 141 and k = 0.85, (d) Method 4, Thr = 138 and k = 0.8, (e) Average of the four methods.

Figure 2 shows the results provided by the proposed system up to the next step, for a dense glandular breast, where the microcalcifications are highlighted, using the morphological filtering (2c). The morphological dilation increased the size of the microcalcifications with the aim of focusing the visualization and localization of these anomalies by the radiologists; this is the most useful aspect of the system.

Figure 3 shows the original image of a breast that contains spiculated masses and the progress of the algorithm, showing the increase in contrast, until reaching the mass detection. For this image, the CIR reached its maximum value in 10 iterations.

The performance of the system is shown in comparison with the base annotation, from the 115 images evaluated by the radiologist using the proposed system (Table 1).

In [4] 100 cases of the same BD have been used, but under the paradigm of artificial intelligence. They have obtained 94 true positives, 4 false positives and 2 false negatives. Three different algorithms were used using machine learning [18] with 161 images from the MIAS database to classify breast lesions, using 5 different pixel size

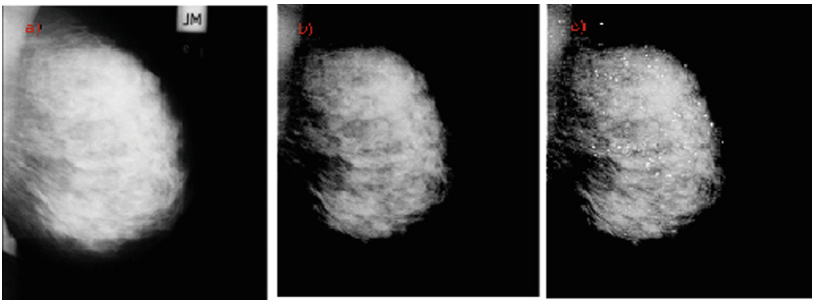

Fig. 2. (a) Original image. (b) Segmented image preprocessed, readjusted, cleaned of artifacts and with the microcalcifications detected in their real size. (c) Image with enhanced microcalcifications.

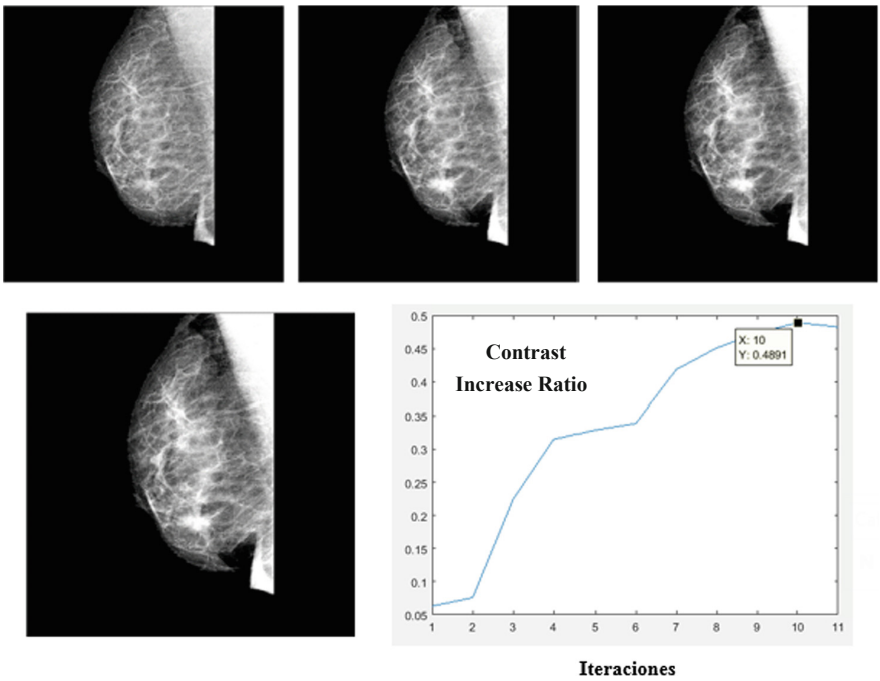

Fig. 3. Result of the detection algorithm and mass enhancement image.

Table 1. Evaluation of the performance of the proposed CAD system.

Accuracy (%)	Precision (%)	Sensitivity (%)	Specificity (%)
90.4	92	93.2	85.3

values and 5 methods of texture analysis, obtaining AUC values between 40 and 78%. The adaptive thresholding is used and 170 images from the BD MIAS [3] and they obtained a sensitivity of 93% and a rate of 0.62 false positives (microcalcifications) per image. In [17] they use segmentation of the gland in the 322 images of the MIAS BD by the Otsu method, thresholding with Wavelet focus and detection by one-dimensional Tsallis Entropy. They obtained AUC values between 87 and 92%. In [7] the 322 images of the MIAS BD were used again to detect masses, using a k-means conglomerate algorithm and analysis of principal components for classification. They obtained an accuracy of 92.7% in non-dense breasts and 79.17% in dense breasts; they also obtained 5 false positives and 2 false negatives for each type of breast. In this sense, it can be stated that the results of the proposed CAD system are in the environment of those reported by other authors using other methods of segmentation-detection and/ or classification, for the same database.

All the calculations were below 30 s, in a common laptop computer, with an Intel P6 Pro-crossover, with 6 GB of RAM. The proposed CAD system proved to be efficient and can be used under conditions of clinical routine to facilitate the diagnosis.

4 Conclusions

For the detection of breast lesions images in mammography a new CAD system was proposed. This system allowed the best edge enhancement with the convolution filter H4. With this, the spatial resolution was improved without introducing excessive noise. All the artifacts were satisfactorily eliminated from the combination of Laplacian segmentation, opening of binary areas and determination of binary related components. The mammary gland was successfully segmented from the average of three global thresholding methods, based on entropy and image readjustment. The microcalcifications were detected from the morphological filtering. The masses were satisfactorily detected after implementing an iterative method for the improvement of image contrast. The proposed CAD system presented good performance index.

Conflict of Interest. The authors declare no conflict of interests.

References

1. Papadopoulos, A., Fotiadis, D., Costaridou, L.: Improvement of microcalcification cluster detection in mammography utilizing image enhancement techniques. Comput. Biol. Med. **38**(10), 1045–1055 (2008)
2. Arnau, O., Torrent, A., Llado, X., Tortajada, M., Tortajada, L.S., et al.: Automatic microcalcification and cluster detection for digital and digitised mammograms. Knowl.-Based Syst. **28**(4), 68–75 (2012)
3. Anitha, J., Dinesh, P., Pandian, I.: A dual stage adaptive thresholding (DuSAT) for automatic mass detection in mammograms. Comput. Methods Programs Biomed. **138**(10), 93–104 (2017)

4. López, Y., Novoa, A., Guevara, M., Quintana, N., Silva, A.: Computer aided diagnosis system to detect breast cancer pathological lesions. In: Iberoamerican Congress on Pattern Recognition, pp. 453–460. Springer, Heidelberg (2008)
5. Maitra, I., Sanjay, N., Kumar, S.: Identification of abnormal masses in digital mammography images. Int. J. Comput. Graph. **2**(1), 17–24 (2011)
6. Burcin, K., Vasif, V., Turhan, K.: A novel automatic suspicious mass regions identification using Havrda & Charvat entropy and Otsu's N thresholding. Comput. Methods Programs Biomed. **114**(3), 349–360 (2014)
7. Oliveira-Silva, L., Kardec-Barros, A., Vinicius- Lopes, M.: Detecting masses in dense breast using independent component analysis. Artif. Intell. Med. **80**(7), 29–38 (2017)
8. Babu, P., Rajamani, V.: Evolutionary algorithm based optimized histogram modification for contrast enhancement of mammogram images. J. Med. Imaging Health Inform. **6**(2), 518–525 (2016)
9. Sundarama, M., Ramar, K., Arumugam, N., Prabin, G.: Histogram modified local contrast enhancement for mammogram images. Appl. Soft Comput. **11**(8), 5809–5816 (2011)
10. Mustra, M., Grgic, M.: Robust automatic breast and pectoral muscle segmentation from scanned mammograms. Sig. Process. **93**(10), 2817–2827 (2013)
11. Sheeba, J., Parasuraman, S., Kadirvelu, A.: Contrast enhancement and brightness preserving of digital mammograms using fuzzy clipped contrast-limited adaptive histogram equalization algorithm. Appl. Soft Comput. **42**(5), 167–177 (2016)
12. Chang, C., Du, Y., Wang, J., Guo, S., Thouin, P.: Survey and comparative analysis of entropy and relative entropy thresholding techniques. IEEE Proc. Vis. Image Signal Process. **153**(6), 837–850 (2006)
13. Yan, H., Liu, J., Yang, D., Wang, P.: An improved algorithm of the maximum entropy image segmentation. In: Fifth International Conference on Intelligent Systems Design and Engineering Applications, pp. 157–160. IEEE, Zhangjiajie (2014). https://doi.org/10.1109/isdea.2014.255
14. Kapur, J., Sahoo, P.: A new method for gray-level picture thresholding using the entropy of the histogram. Comput. Vis. Graph. Image Process. **29**(3), 273–285 (1985)
15. Prasanna, K., Gurdial, A.: Image thresholding using two-dimensional Tsallis–Havrda–Charvát entropy. Pattern Recogn. Lett. **27**(6), 520–528 (2006)
16. Abdulkader, H., Abiyev, R.: Shape and texture features for the identification of breast cancer. In: Proceedings of the World Congress on Engineering and Computer Science. Newswood, San Francisco (2016)
17. Mehdi, M., Gargour, B., Ayed, A., Masmoudi, D., Sellami, R.: An efficient microcalcifications detection based on dual spatial/spectral processing. Multimedia Tools Appl. **76**(11), 13047–13065 (2017)
18. Abdel-Nasser, M., Melendez, J., Moreno, A., Puig, D.: The impact of pixel resolution, integration scale, preprocessing, and feature normalization on texture analysis for mass classification in mammograms. Int. J. Opt. (2016). http://dx.doi.org/10.1155/2016/1370259. ID 1370259